

# Unilateral Flaccid Paraplegia Associated with Chronic Granulomatous Disease

Shabnam Pourhamdi<sup>1\*</sup>, Payam Mohammadinejad<sup>1</sup>

<sup>1</sup> Research Center for Immunodeficiencies, Pediatrics Center of Excellence, Children's Medical Center, Tehran University of Medical Sciences, Tehran, Iran

## Abstract

Chronic Granulomatous Disease (CGD) can be associated with several neurological complications. Abscess in the brain in patients diagnosed with CGD has been reported in several publications. Different pathogens have been linked with brain abscess development including fungal or bacterial infections. Other neurologic complications may include white matter disease and formation of a granulomatous lesion in the central nervous system.

In addition to these common reports, observation of leptomeningeal, along with focal brain infiltration by pigmented, lipid-laden macrophages, fungal brain infection, Aspergillus abscess resembling a brain tumor, spinal cord infection by Aspergillus, and fungal granuloma of the brain have also been described. Physicians should be aware of Streptococcus- and Candida-induced meningitis in a selected group of CGD patients as well. Herein, we report a case of the attenuated ill-defined lesion in the right cerebellar hemisphere in a CGD patient without involvement of the sinuses or lungs.

**Keywords:** Gastrointestinal manifestation, Enteropathy phenotype, Common variable immunodeficiency, Diagnostic delay

---

\*Corresponding Author: Shabnam Pourhamdi

1. Research Center for Immunodeficiencies, Pediatrics Center of Excellence, Children's Medical Center, Tehran University of Medical Sciences, Tehran, Iran

E-mail: pourhamdis@yahoo.com

## Introduction

Chronic Granulomatous Disease (CGD) is the most frequent immunodeficiency affecting the phagocyte, with patients presenting repeated infections with bacterial and fungal pathogens, as well as granulomas in different tissues (1, 2). CGD is caused by defects in the NADPH oxidase system leading to the defective killing of pathogenic organisms (3-5). This can result in infections with different intracellular pathogens including *Staphylococcus aureus*, *Pseudomonas species*, *Nocardia species*, along with fungal infections including *Aspergillus species* and *Candida albicans*. Involvement of the neurological system can contribute to severe morbidity and mortality in the CGD patients (6, 7).

Different pathogens have been linked with brain abscess development including *Scedosporium prolificans*, *Alternaria infectoria*, *Salmonella enterica subspecies houtenae*, and *Aspergillus* (2, 8). In particular, aspergillus is a fungus whose inhalation may cause localized infection in the lungs, sinuses, or other sites in a CGD patient. In critically ill patients, invasive aspergillosis has a poor prognosis, particularly if it affects cerebral tissue (5, 6). The mortality rate of cerebral aspergillosis may be as large as 60% and therefore it needs immediate clinical management (4).

We report a critical CGD case of the cerebral lesion without the involvement of other organs at the time of neurological presentation. The interesting educative points about this case include paying attention to the possibility of cerebral aspergillosis as well as an unusual combination of complications in the case.

## Case report

The patient was a 2-years-and-4-month-old boy with a diagnosis of CGD at the age of 2 who was referred to our hospital with left side hemiparesis and general weakness. Two weeks before the admission, he developed erythema and pruritus across the entire palmar surface of both hands. At

the same time, the patient suffered from drooling and odynophagia but was able to drink and eat with some difficulties. One week later, erythema, edema, and tenderness were observed at the dorsal surface of his right hand which also involved the fingers. The patient received cephalexin, ciprofloxacin, and mupirocin for the management of cellulitis and cetirizine for pruritus relief. The day after, he began to develop general weakness and atonia in the left side extremities. Right side extremities also started to develop atonia but to a much lesser degree. The patient lost the ability to stand at this point.

The ability to sit and maintain head position and the control of defecation and urination were also lost 3 days later. The erythematous lesion of the right hand progressed to abscess formation which simultaneously remitted with the drainage of pus through the developed fistula at the fingertips. The day before the admission, the patient developed mild ptosis of the left eyelid. The patient's mother also mentioned cold sweating from the beginning of symptoms but no fever, diarrhea, vomiting, and symptoms of upper respiratory infections.

In his past medical history, the patient was the result of a non-consanguineous marriage with no history of similar problems in other members of the family. He was well until the age of 6 months, when he started to suffer from recurrent respiratory infections. At that time, the diagnosis of gastroesophageal reflux disease (GERD) and hyper-reactive airways disease (HAD) had been suspected. At the age of 14 months, he developed tuberculous adenitis (scrofula) after receiving the BCG vaccine. At the age of 2 years, he was admitted to our hospital with suppurative cervical and inguinal adenitis of the right and left sides respectively, fever, and respiratory distress. Chest X-ray and HRCT showed two large pneumatoceles in the superior lobe of the left lung and necrotizing pneumonia with atelectasis in the superior lobe of the right lung. Cultures from sputum and the suppurative cervical adenitis showed the growth of *Klebsiella pneumoniae*. Laboratory investigations confirmed the diagno-

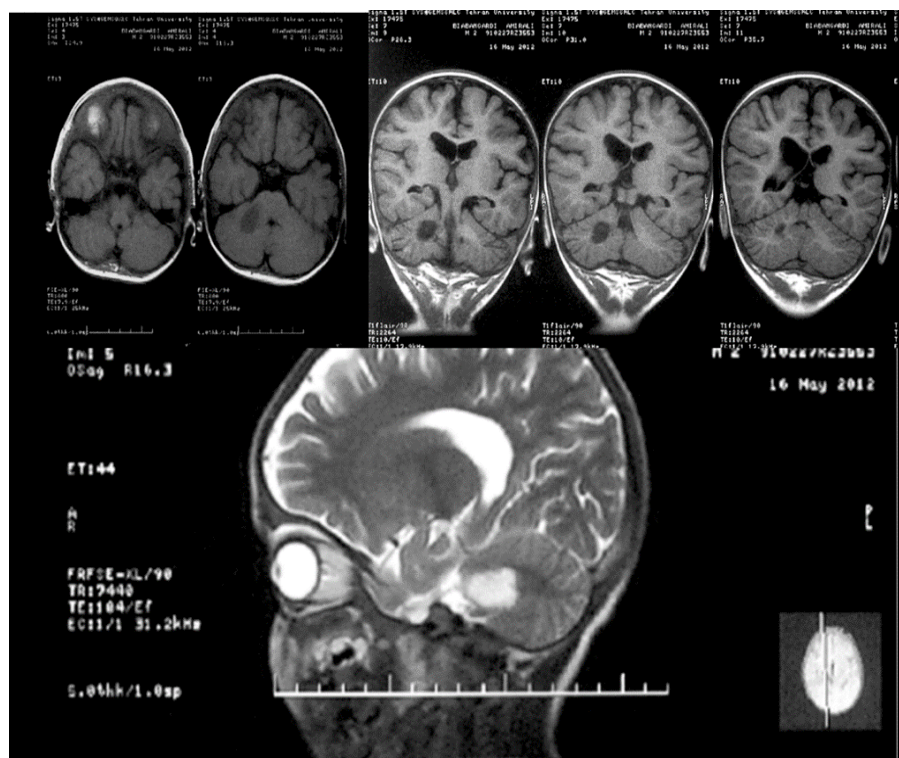
sis of CGD at this point and G6PD deficiency was also reported.

Physical examination revealed mild ptosis and miosis at the left eye. Examination of the left eye also showed strabismus, along with lateral and downward gaze but no nystagmus or staring. The pupillary light reflex of the left eye was also impaired. The mentioned presentation raised the suspicion toward the involvement of the left third cerebral nerve. Round, indurate, erythematic patchy lesions with some papules were observed at both lower extremities with a 2\*3 cm area each just below the knee, right upper quadrant of abdomen with a 5\*3 cm area, and a small area on the scalp. Post-nasal drip (PND) was observed at the examination of the pharynx. Lymphadenopathy was not present in cervical and axillary regions. Muscular tone and force were reduced in all four extremities mainly on the left side. Deep tendon reflexes were normal; however, Babinski's reflex was downward on the left side and upward on the right side.

Laboratory data were as follows: white blood cell count: 12370 (normal range, 5500-15500) with 44% neutrophils, 37% lymphocytes and 9% monocytes, hemoglobin: 11.4 g/dL (normal range,

11-14 gr/dL), hematocrit: 35.4% (normal range, 31-41%), mean corpuscular volume: 69 fL (normal range, 80-99 fL), platelet: 349000 (normal range, 150,000-400,000), PPD test: 25 mm (normal range < 10 mm). Mild anisocytosis, poikilocytosis, and hypochromia were also reported in the blood smear. Blood culture was positive for *Pseudomonas aeruginosa* organism. Bronchoalveolar lavage (BAL) was negative for tuberculosis.

An axial brain CT scan showed a hypo-attenuated ill-defined lesion in the right cerebellar hemisphere with expansion to the midbrain. Midline shift and hydrocephaly were not seen but a diffuse, mild cerebellar atrophy was observed. Brain MRI revealed lesions in the medial cerebellar ankle. A smaller separated abscess-like lesion in midbrain was noted indicating a cerebral vascular accident or abscess (**Figure 1**). At this point, patient was considered to have brain abscess followed by septicemia. Since the abscess was not large enough to be aspirated, and to cover all agents associated with differential diagnosis, intravenous injection of ceftazidime, vancomycin, meropenem, and metronidazole was started for him and patient responded well to this combined therapy.



**Figure 1.** The brain image of a CGD patient associated with unilateral paraplegia showing a hypo-attenuated ill-defined lesion in the right cerebellar hemisphere with expansion to the midbrain. Midline shift and hydrocephaly were not seen, but a diffuse, mild cerebellar atrophy was observed. A smaller separated abscess-like lesion in midbrain was also observed indicating a cerebral vascular accident or abscess.

## Discussion

A combination of septicemia with *Pseudomonas aeruginosa* and neurologic manifestation of this CGD patient made the targeted treatment challenging (1, 7). The majority of previously reported impaired patients with defective NADPH oxidase activity of the phagocytes with invasive brain lesions indicated that the pathogenic organism (catalase-positive microorganisms, fungal infections, and even mycobacterium agents) may be mixed in an immunodeficiency condition (4, 9). Meanwhile, the physicians should be aware that virulent and drug-resistant forms of microorganism may be responsible for these complications, since abscesses of the brain are uncommon and have rarely been documented in CGD patients (5, 7). Thus, monotherapy and routine antimicrobial agents may often be ineffective leading to surgical excision with a high-risk intervention and consequential side-effects. Itraconazole, interferon, as well as voriconazole could be added in cases of suspicion to *Aspergillus* (2).

In CGD patients, treatment of the source of the infections should be tracked since several invasion routes could be involved including hematogenously from the pulmonary organs or passage from the paranasal sinuses (5, 10). All nonspecific signs are important in follow-up visits of CGD patients since focal neurologic signs, altered mental status, and headaches in the absence of fever may be the only present findings in many patients (9). Moreover, extra care would be required particularly when CGD patients undergo conditioning for hematopoietic stem cell transplantation or receive high-dose corticosteroids (6, 8).

Invasive intracranial lesions of the brain in CGD affected cases have the same imaging pattern as other primary immunodeficiencies with infections that cause brain abscesses. Note that generally CT scan is more specific than MRI (3). Different locations of brain abscess in the affected individual could be expected including the majority of perforator artery territories, thalami as well as basal ganglia. In few

cases, mistreatment and mismanagement have been linked to epidural abscess and skull osteomyelitis mainly in association with fungal infections. In case of penetration and consequently ischemic brain parenchyma, surgical operations can be effective in CGD patients and can significantly reduce mortality (8, 10).

## Conclusion

To improve the condition of CGD patients and prevent neurological manifestations, all first line physicians should be sensitive to important hints to recognize them and prevent delay in diagnosis. Further, correct clinical and precise radiological follow-up of high-risk individuals with already established diagnosis of CGD should be considered; and if required, urgent operational intervention should be adopted.

**Conflicts of interest:** The authors declare that they have no conflicts of interest.

## References

1. Marciano BE, Spalding C, Fitzgerald A, Mann D, Brown T, Osgood S, et al. Common severe infections in chronic granulomatous disease. *Clin Infect Dis*. 2015;60(8):1176-83.
2. Martire B, Rondelli R, Soresina A, Pignata C, Broccoletti T, Finocchi A, et al. Clinical features, long-term follow-up and outcome of a large cohort of patients with Chronic Granulomatous Disease: an Italian multicenter study. *Clin Immunol*. 2008;126(2):155-64.
3. Drouin-Garraud V, Belgrand M, Grunewald S, Seta N, Dacher JN, Henocq A, et al. Neurological presentation of a congenital disorder of glycosylation CDG-Ia: implications for diagnosis and genetic counseling. *Am J Med Genet*. 2001;101(1):46-9.
4. Ma JS, Chen PY, Lau YJ, Chi CS. Brain abscess caused by *Salmonella enterica* subspecies *houtenae* in a patient with chronic granulomatous disease. *J Microbiol Immunol Infect*. 2003;36(4):282-4.
5. Segal BH, Veys P, Malech H, Cowan MJ.

- Chronic granulomatous disease: lessons from a rare disorder. *Biology of blood and marrow transplantation Biol Blood Marrow Transplant.* 2011;17(1):123-31.
6. Schwenkenbecher P, Neyazi A, Donnerstag F, Ringshausen FC, Jacobs R, Stoll M, et al. Chronic Granulomatous Disease First Diagnosed in Adulthood Presenting With Spinal Cord Infection. *Front Immunol.* 2018;9:12-58.
  7. Koker MY, Camcioglu Y, van Leeuwen K, Kiliç SS, Barlan I, Yilmaz M, et al. Clinical, functional, and genetic characterization of chronic granulomatous disease in 89 Turkish patients. *J Allergy Clin Immunol.* 2013;132(5):1156-63.
  8. Rawat A, Bhattad S, Singh S. Chronic Granulomatous Disease. *Indian J Pediatr.* 2016;83(4):345-53.
  9. Nwawka OK, Nadgir R, Fujita A, Sakai O. Granulomatous disease in the head and neck: developing a differential diagnosis. *RadioGraphics.* 2014;34(5):1240-56.
  10. Danziger RN, Goren AT, Becker J, Greene JM, Douglas SD. Outpatient management with oral corticosteroid therapy for obstructive conditions in chronic granulomatous disease. *J Pediatr.* 1993;122(2):303-5.